CASE REPORT

UDC: 616-056.7::576.316
DOI:10.2298/VSP1207620S

Fabry disease, do we think enough about this multisystemic disorder? – A presentation of three cases in a Serbian family

Fabrijeva bolest, razmišljamo li dovoljno o ovom multisistemskom poremećaju? Prikaz tri bolesnika iz jedne porodice u Srbiji

Dejan Sakač*, Goran Koraćević†, Tatjana Pavlica‡, Slobodan Sekulić§

***Clinic of Cardiology, Institute of Cardiovascular Diseases of Vojvodina, Sremska Kamenica, Serbia; †Clinic of Cardiology, Clinical Center Niš, Niš, Serbia; ‡Department of Biology and Ecology, School of Natural Scienes and Mathematics, University of Novi Sad, Novi Sad, Serbia, §Clinic of Neurology, Clinical Center of Vojvodina, Novi Sad, Serbia**

Abstract

Background. Fabry Disease is a rare, X-chromosomal inherited lysosomal storage disease with a consequent intracellular accumulation of neutral glycosphingolipids in various tissues. This can cause skin and ocular lessions, progressive renal, cardiac or cerebrovascular disorders. If a person in a family has Fabry disease, other family members including even extended relatives, may also be at risk. **Case report.** We presented three cases pointed out various manifestation of Fabry disease, that illustrate a possible cause for otherwise unexplained cardiac hypertrophy and various rhythm and conduction abnormalities. **Conclusion.** Although most symptoms begin in childhood, various manifestations often lead to misdiagnosis and clinical diagnosis is frequently delayed for many years, even decades. Enzyme replacement therapy has become available, pointing out the importance of early diagnosis so that treatment can be initiated before irreversible organ damage.

Key words:
fabry disease; chromosome aberrations; genetic diseases, inborn; diagnosis, differential.

Apstrakt

Uvod. Fabrijeva bolest je retka, X-hromozomno nasledna lizozomna bolest nakupljanja sa posledičnim intraćelijskim nagomilavanjem neutralnih glikosfingolipida u različitim tkivima. To može da uzrokuje patološke promene kože i očiju, progresivne bubrežne, srčane ili cerebrovaskularne poremećaje. Ako jedna osoba u porodici ima Fabrijevu bolest, i drugi članovi porodice, uključujući čak i širu rodbinu, takođe mogu biti ugroženi. **Prikaz bolesnika.** Prikazana su tri bolesnika iz jedne porodice sa ciljem da se ukaže na vrlo različite manifestacije Fabrijeve bolesti i na moguć uzrok, inače, neobjašnjive hipertrofije miokarda i poremećaje srčanog ritma i provođenja. **Zaključak.** Iako većina simptoma počinje u detinjstvu, različite manifestacije bolesti često dovode do pogrešne dijagnoze i otkrivanje bolesti često kasni mnogo godina, čak i decenija. Enzimska supstituciona terapija postala je dostupna, ističući važnost ranog utvrđivanja bolesti, tako da se lečenje može započeti pre nastanka ireverzibilnih oštećenja organa.

Ključne reči:
fabrijeva bolest; hromosomi, anomalije; nasledne bolesti; dijagnoza, diferencijalna.

Introduction

Fabry disease (FD), also known as morbus Anderson-Fabry, is a rare X-chromosomal inherited lysosomal storage disease caused by mutations in the galactosidase alpha gene (GLA gene) that result in deficient activity of the lysosomal enzyme α-galactosidase A. The ensuing enzyme deficiency results in intracellular accumulation of neutral glycosphingolipids (primarily globotriaosylceramide) in the vascular endothelium, particularly in kidneys, heart, nervous system, skin or in other cell types [1, 2]. The incidence of FD is estimated to range from 1 : 40,000 to 1 : 117,000 worldwide, but these figures likely underestimate the burden of disease because its manifestations often lead to misdiagnosis and underreporting [3]. Although most symptoms begin in childhood, clinical diagnosis is frequently delayed. Female carriers are at risk of developing disease, but this tends to be milder and more slowly progressive than in males. In males, symptoms can begin in the first decade of life with acroparesthesia and pain, febrile crises, hypohidrosis, heat intolerance, gastrointestinal disturbance and cutaneous angiokeratomas. From the second decade onward, patients can develop proteinuria and

Correspondence to: Dejan Sakač, Institute of Cardiovascular Diseases of Vojvodina, Institutski put 4, 21 204 Sremska Kamenica, Serbia. Phone: +381 21 480 5 100. E-mail: dejsakac@open.telekom.rs

neurologic manifestations [4]. Data about enzyme replacement therapy suggest that it has the potential to attenuate and possibly reverse some aspects of organ involvement [5, 6].

Case report

There is no documentation about index patient (grandmother), but there are data about her son from the second marriage – case 1, her granddaughter – case 2, as well as for her son from the first marriage – case 3 (Figure 1).

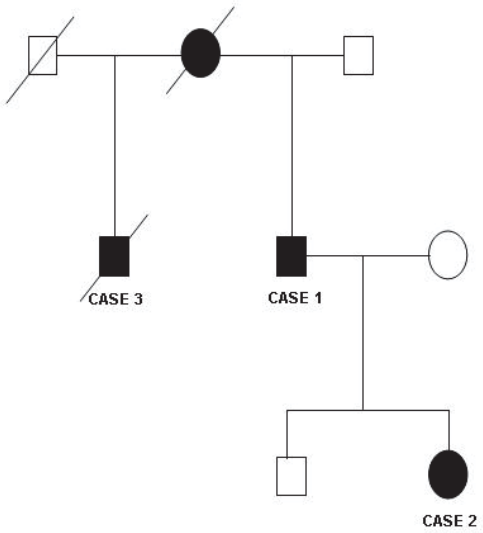

Fig. 1 – Family history of three patients with Fabry disease (cases 1–3). Males are denoted by squares, females by circles. Filled symbols indicate those with Fabry disease. Open symbols indicate unaffected subjects. The dashes indicate deceased patients

fibrillation with hypertrophy of the left ventricle (Figure 2). The patient was normotensive, but echocardiogram revealed concentric hypertrophy of the left ventricle (interventricular septum thickness 1.5 cm, posterior wall thickness 1.4 cm in end-diastole) with normal ejection fraction. Then, signs of forgetfulness and dormancy has been noticed. Magnetic resonance imaging of the endocranium was without pathological findings. As palpitations repeated, the patient underwent ergometry (to the 3rd minute, 100W, Bruce protocol), with the normal finding. During laboratory screening proteinuria was also registered (997.3 mg/L; referent values < 140 mg/L) while creatinine levels were normal. Finally, data of positive family history of an early death of his half-brother raised suspicion of inherited disease. Blood tests to measure the level of alpha-galactosidase A activity were performed at the Institute of Medical Biochemistry, Clinical Center of Serbia, Belgrade, and revealed low activity (0.81 nmoL/h/mg, referent values > 60 nmoL/h/mg proteins from leucocytes). Measurement was repeated in Hamburg University Medical Center, Germany, which registered activity below its referent range (16.92 pmoL/spot; referent values 200–2000 pmoL/spot, from dried blood). A subsequent genetic analysis was performed in the University Medical Center, Ljubljana, Slovenia (genomic DNA was extracted from peripheral blood, DNA regions of the α-galactosidase A gene were analyzed by polymerase chain reaction after amplifying each of α-galactosidase A exons and sequencing the opposite strand), where a hemizygous nucletid substitution c.334C > G was registered, resulting in change of aminoacid arginine to glycine (p.R112G). This confirmed the diagnosis of FD (Table 1).

Case 2 – the daughter of the case sensed paresthesia at the age of 14, now aware of inherited disease in the family,

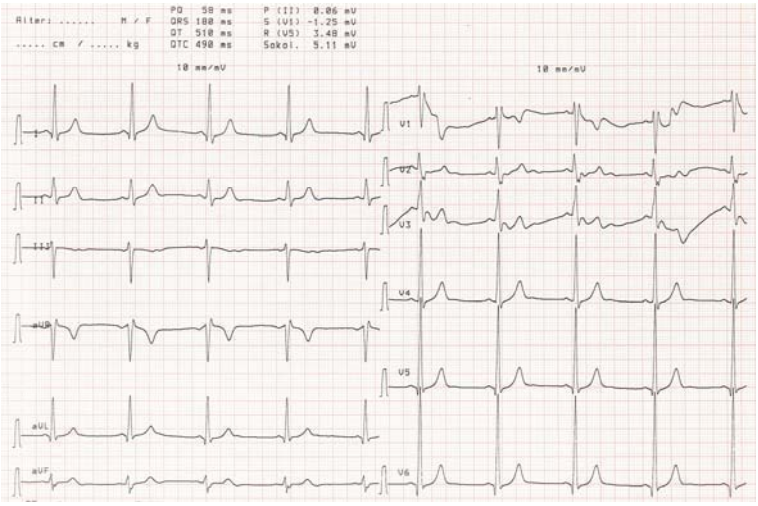

Fig. 2 – A standard 12-lead electrocardiogram demonstrating left ventricular hypertrophy by voltage criteria and incomplete right bundle branch block

Case 1 – a 21-year-old male, sensed upper abdominal pain with occasional episodes of diarrhea. He repeatedly underwent gastrointestinal investigation, including gastroscopy, which found no abnormalities. At the age of 40 he felt palpitations, electrocardiogram (ECG) registered paroxysmal atrial

she went through ophthalmology evaluation which registered discrete signs of corneal opacities (*cornea verticillata*) and radial lens opacities. A subsequent genetic analysis was performed in Slovenia which confirmed nucletid substitution, as her father's findings.

Table 1

Gold-standard methods for confirmation Fabry disease

Gender	Diagnostic step 1	Diagnostic step 2
Male	Alpha-galactosidase A activity in peripheral leucocytes (or plasma)	Alpha-galactosidase A gene sequencing and identification of disease - causing mutation
Female	Alpha-galactosidase A gene sequencing and identification of disease - causing mutation*	

*** Alpha-galactosidase A activity in peripheral leucocytes is not preferred and plasma levels are unreliable**

Case 3 – finally, family got the part of medical documentation of the grandmother's oldest son, of her first marriage, who at that time had started living with his father. The father noticed signs of intellectual deterioration, impared memory and lethargy in his late teens. The deterioration was progressive with new signs, such as balance disturbances and ataxia. Clinical investigation was performed in the United Kingdom (in 1982) where urine examination showed a markedly increased concentration of ceremide trihexoside and ceremide dihexoside while brain biopsy showed accumulation of Periodic acid-Schiff stain (PAS) positive, birefringent and sudanophilic material. Soon, at the age of 32, the patient died.

Discussion

Historically, FD has been believed to be a rare disease [1–3]. However, a recent study using an alpha-galactosidase A assay on blood spots from 37,104 consecutive Italian male neonates, has demonstrated a prevalence of 0.03% and an incidence of alpha-galactosidase A deficiency of 1 in 3,100. These data are in accordance with the findings of studies that have reported a prevalence of 0.2–1.2% in patients with end-stage renal disease on hemodialysis and 4.9% in men with cryptogenic stroke [4]. Although many symptoms occur in childhood, a proper diagnosis can be delayed by as much as 10–15 years. Because of typical skin lesions, dermatologists are often the first to make the diagnosis. Cardiac involvement is present early in life, but is not detected clinically until the third or fourth decade [7, 8]. Cardiac abnormalities in FD are usually presented as left myocardial hypertrophy, various rhythm and conduction disturbances. In all cases with unexplained cause of cardiac hypertrophy or various rhythm and conduction abnormalities, always think about FD as a differential diagnosis. Enzyme replacement therapy (ERT) for FD was introduced in Europe in 2001. ERT has been shown to clear accumulated glycosphingolipids (Gb 3) in blood vessels as well as from other organs [9, 10]. ERT is recommended in all male with FD, children and female carrier with signs and symptoms of FD. Follow-up and additional studies are necessary to fully evaluate long term efficacy of ERT in children with FD [8, 10, 11]. There are no reliable data about the incidence of FD in Serbia, so further investigation and screening are desirable.

Conclusion

Although most symptoms begin in childhood, various manifestations often lead to misdiagnosis and confirmation of FD is frequently delayed. The incidence is obviously underestimated. Prenatal screening, screening of asymptomatic relatives and predictive testing provide an opportunity to detect preclinical disease and start treatment to prevent long-term complications.

R E F E R E N C E S

1. *Mehta A, Ricci R, Widmer U, Dehout F, Garcia de Lorenzo A, Kampmann C,* et al. Fabry disease defined: baseline clinical manifestations of 366 patients in the Fabry Outcome Survey. Eur J Clin Invest 2004; 34(3): 236−42.
2. *Zarate YA, Hopkin RJ.* Fabry's disease. Lancet 2008; 372(9647): 1427−35.
3. *Fujii H, Kono K, Goto S, Onishi T, Kawai H, Hirata K,* et al. Prevalence and cardiovascular features of Japanese hemodialysis patients with Fabry disease. Am J Nephrol 2009; 30(6): 527−35.
4. *Perry E.* Anderson–Fabry disease: an important differential diagnosis in patients with unexplained left ventricular hypertrophy. Heart Metab 2006; 33: 25−9.
5. *O'Mahony C, Elliott P.* Anderson-Fabry disease and the heart. Prog Cardiovasc Dis 2010; 52(4): 326−35.
6. *Linhart A, Kampmann C, Zamorano JL, Sunder-Plassmann G, Beck M, Mehta A,* et al. Cardiac manifestations of Anderson-Fabry disease: results from the international Fabry outcome survey. Eur Heart J 2007; 28(10): 1228−35.
7. *Spada M, Pagliardini S, Yasuda M, Tukel T, Thiagarajan G, Sakuraba H,* et al. High incidence of later-onset fabry disease revealed by newborn screening. Am J Hum Genet 2006; 79(1): 31−40.
8. *Eng CM, Germain DP, Banikazemi M, Warnock DG, Wanner C, Hopkin RJ,* et al. Fabry disease: guidelines for the evaluation and management of multi-organ system involvement. Genet Med 2006; 8(9): 539−48.
9. *Charron P, Arad M, Arbustini E, Basso C, Bilinska Z, Elliott P,* et al. Genetic counselling and testing in cardiomyopathies: a position statement of the European Society of Cardiology Working Group on Myocardial and Pericardial Diseases. Eur Heart J 2010; 31(22): 2715−26.
10. *Hughes DA, Elliott PM, Shah J, Zuckerman J, Coghlan G, Brookes J,* et al. Effects of enzyme replacement therapy on the cardiomyopathy of Anderson-Fabry disease: a randomised, double-blind, placebo-controlled clinical trial of agalsidase alfa. Heart 2008; 94(2): 153−8.
11. *Desnick RJ, Brady R, Barranger J, Collins AJ, Germain DP, Goldman M,* et al. Fabry disease, an under-recognized multisystemic disorder: expert recommendations for diagnosis, management, and enzyme replacement therapy. Ann Intern Med 2003; 138(4): 338−46.

Received on December 30, 2010.
Revised on April 4, 2011.
Accepted on May 19, 2011.