International Journal of Pharmacology 4 (5): 352-360, 2008
ISSN 1811-7775
© 2008 Asian Network for Scientific Information

Acute Toxicity Study and Phytochemical Screening of Selected Herbal Aqueous Extract in Broiler Chickens

[1]S.R. Hashemi, [1]I. Zulkifli, [2]M. Hair Bejo, [3]A. Farida and [4]M.N. Somchit
[1]Department of Animal Science,
[2]Department of Veterinary Pathology and Microbiology,
[3]Department of Food Sciences and Technology,
[4]Department of Biomedical Sciences, Universiti Putra Malaysia,
43400 UPM Serdang, Selangor, Malaysia

Abstract: In order to collect ethnobotanical information about growth and health promoter plants as feed additive in broiler chickens, five medicinal plants *Euphorbia hirta*, *Solanum torvum*, *Zingiber officinale*, *Curcuma longa* and *Zingiber zerumbet* used by traditional medical practitioners for the treatment of several ailments of microbial and non-microbial origins were investigated for phytochemical screening and acute toxicity study. A total of 30 female broiler chicks were obtained. At 21 days of age, the chicks were allocated at random into six groups. Five chickens were assigned at random to each treatment in five replicates and kept in 30 cages (one chickens per cage) till five weeks of age. Five groups were administered a single oral dose of 2,000 mg kg^{-1} b.wt. while 5 mL distilled water was given to the control group of birds as placebo. Phytochemical screening study showed that plant contained volatile oils, tannins, alkaloids, saponins, flavonoids. Alkaloids and steroids were only found in the aqueous extract of *Euphorbia hirta.* Tissues were harvested and processed for photomicrographic examinations. Macro and microscopic observations indicated no alteration in liver and kidneys of the treated birds with 2000 mg kg^{-1} of selected herbal plants extract. In the hematological study, a highly significant decrease was observed in AST, ALT, ALP level of broiler group receiving the aqueous extract of *E. hirta* 14 after of administration. Acute toxicity study indicated that water suspensions of selected herbal aqueous extract are not toxic when administered by the oral route to experimental birds at 2000 mg kg^{-1} b.wt. In conclusion, the results obtained in the present study are in agreement to a certain degree with the traditional uses of the plants estimated as prophylaxis against various diseases and promote of health.

Key words: Antimicrobials, broiler, *Euphorbia hirta*, phytochemical, toxicity

INTRODUCTION

Antimicrobials have been used as feed supplement for more than 50 years in poultry feed to enhance the growth performance and to prevent diseases in poultry. Most of the antibiotic growth promoters take action by modifying the intestinal flora, which are associated with poor health and reduced performance of animals. However, in recent years great concern has arisen about the use of antibiotics as growth and health promoters in poultry feed due to emergence of multiple drug resistant bacteria and antibiotic residue effects (Wray and Davies, 2000). There is evidence to suggest that herbs, spices and various plant extracts have appetizing and digestion-stimulating properties and antimicrobial effects (Alçiçek *et al*., 2004; Zhang *et al*., 2005). Plant origin like herbs, spices and various plant extracts are considered to be natural products that consumers would have received an increased attention and as possible alternatives to antibiotic growth promoter in improving broiler performance (Hernandez *et al*., 2004). Knowledge of the chemical constituents of herbal plants not only for the discovery of therapeutic agents, but also for new sources of economic materials is desirable. However, it is important to establish the chemical constituent and safety of herbal plants before they are useful on supplement in poultry diet.

Solanum torvum Swartz (Solanaceae) distributed widely in Southeast of Asia. To date, several alkaloid, steroidal glycosides and long chain hydrocarbons and steroids have been previously isolated from *S. torvum* (Arthan *et al*., 2002). Zingiberaceae is one of the largest families of the plant kingdom. Traditionally, the rhizome of *Zingiber zerumbet* are employed as medicine in relieving

Corresponding Author: I. Zulkifli, Department of Animal Science, Universiti Putra Malaysia, 43400 UPM, Serdang, Selangor, Malaysia

stomachache, macerated in alcohol which is regarded as tonic (Sharifah Sakinah *et al*., 2007). *Zingiber officinale* Roscoe (family, Zingiberaceae), known commonly as ginger. In Ayurveda, ginger is considered as valuable medicine because of its action as rubefacient, antiasthmatic and stimulant to the gastrointestinal tract (Bhandari *et al*., 1998). *Curcuma longa* L., is belongs to the Zingiberaceae family. The powdered rhizome of *C. longa* is considered to be stimulating, carminative, purifying, antiinflammatory and anthelmintic. Externally, the rhizome mixed with alum lime and saltpetre is applied as a paste to wounds, bruises, inflamed joints and sprains (Araujo and Leon, 2001; Khattak *et al*., 2005).

Euphorbia hirta belongs to the family Euphorbiaceae. The plant contains relatively abundant white latex. The latex is capable of causing dermatitis. The plant has been used in traditional medicine for the treatment of cough, coryza, asthma, bronchial affections (Adedapo *et al*., 2005; Hore *et al*., 2006).

As no information exists in the alternative, the objective of the present study was to investigate the safety of *Euphorbia hirta, Solanum torvum*, *Zingiber officinale*, *Curcuma longa* and *Zingiber zerumbet* aqueous extract as a dietary additive in poultry diets.

MATERIALS AND METHODS

Plant materials: Whole plant of *Euphorbia hirta*, edible fruit of *Solanum torvum* and rhizomes of *Zingiber officinale*, *Curcuma longa* and *Zingiber zerumbet* were tested for phytochemical screening and acute toxicity study. Fresh *Euphorbia hirta* was collected in April 2007 from the agriculture gardens in Universiti Putra Malaysia and other plants were obtained from a local market. The plant specimens were identified and authenticated by the Institute of Bioscience, Universiti Putra Malaysia.

Preparation of the extract: Fresh parts of the plant were cleaned, cut into bits and rinsed with distilled water. The plants were air dried at room temperature for 24 h, then oven-dried at temperature of 50°C till they attained a constant weight. The dried plants were then powdered. In order to obtain the plants extracts, 100 g of each dried plant material powder was placed in a flask and distilled water was added (1:10 w/v). The flasks were incubated in a shaking-water bath at 50°C for 48 h and the obtained extracts were filtered using cotton wool and finally filter papers (Whatman® No. 1). The flow-through t were stored in a deep freezer at -80°C overnight and then subjected to freeze drying (Jouan LP3, France) at -50°C; 0.2 mbar for 48 h to obtain water-free extracts. Extracts were then weighed and stored at -20°C till further use.

Phytochemical screening: A qualitative phytochemical test was carried out to detect the presence of volatile oils, alkaloids, tannins, saponins, flavonoids, glycosides, steroids, terpenoids and phenols utilizing standard methods of analysis (Sofowora, 1993; Evans, 1996; Haughton and Raman, 1998). The intensity of the coloration determines the abundance of the compound present. Qualitative phytochemical analysis of the powder of the five plants were determined as follows: for tannins one g plant grinded, then sample was boiled in 20 mL ethanol 70% for 2 min on a hot plate. The mixture was filtered and a portion of the filtrate diluted with sterile distilled water in a ratio of 1:4 and 3 drop of 10% ferric chloride solution added. Blue-black precipitate indicated the presence of tannins. For phenol 2 mL of extract was added to 2 mL of ferric chloride solution ($FeCl_3$); a deep bluish green solution is formed with presence of phenols. The test for alkaloids was carried out by subjecting 5 g ground plant material extracted with 10 mL ammoniacal chloroform and 5 mL chloroform. After filtration, the solution was shaken with 10 drops aqueous sulphuric acid 0.5 M. Creamish precipitate indicated the presence of respective alkaloids. For steroids Liebermann-Burchard reaction was applied. Two hundred milligram plant material boiled in 10 mL chloroform and the mixture was filtered; a 2 mL filtrate was added to 2 mL acetic anhydride and concentrated H_2SO_4. Blue-green ring indicated the presence of steroids and red color indicated the presence of terpenoids. The alcoholic extract (15 mL, corresponding to 3 g of plant material) was treated with a few drops of concentrated HCl and magnesium Ribbon (0.5 g). Pink-tomato red color indicated the presence of flavonoids. Froth test for saponins was used. The test for saponin was carried out by subjecting 5 g of the plant powder extracted with 15 mL methanol. After evaporation, residue was shaken vigorously with ethyl ether and 5 mL HCl 2N. Precipitate indicated the presence of saponin. For detection of volatile oils, 1 g fresh plant sample was boiled in 10 mL petroleum ether, filtered and then 2.0 mL of extract solution was shaken with 0.1 mL dilute sodium hydroxide and a small quantity of dilute hydrochloric acid. A white precipitate indicated the presence of volatile oils (Dahiru *et al*., 2006). The extract was also tested for free glycoside. Fehling's solution (A and B) was added to the extract and the solution was heated on a hot plate and brick-red precipitate indicated the presence of glycosides.

Acute toxicity study: Acute toxicity test was performed according to the World Health Organization (WHO) guideline (WHO, 2000) and the Organization of Economic Co-operation and Development (OECD) guideline for testing of chemicals (OECD, 2001). A total of 30 one-day-

old commercial female broiler chicks (Cobb 500) were obtained from a local hatchery. Female broilers were selected because they are generally more sensitive than males to toxicity study (OECD, 2002). Upon arrival, the chicks were individually wing-tagged, weighed and assigned in battery cages with wire floors till 21 days. For evaluation of high doses of aqueous extract of the plant, at 21 days of age, the chickens were weighed (850±21 g) and randomly divided into 6 groups; each group was further subdivided into 5 replicates with one chick per cage. One chick was designated as an experimental unit. Five groups were administered a single oral dose of 2,000 mg kg^{-1} b.wt. with aqueous extract of selected plants while distilled water was given to the control group of broiler as placebo. Birds were fed NRC-type (National Research Council, 1994) experimental diets from Days 1 to 35 (Table 1). The birds were fed starter diet from 1 to 21 days of age and finisher diet from 22 to 35 days of age. Feed and water were provided *ad libitum*. Light was provided for 24 h day^{-1}. All chickens were observed at the first, second fourth, six hour and once daily thereafter over 14 days [Center for Drug Evaluation and Research (CDER)] for clinical signs of toxicity.

Histopathological studies: On day 35, all the birds were killed and their livers and kidneys were removed. Tissues were fixed in 10% neutral-buffered formalin for 24 h, before being processed for routine paraffin embedding. Tissues were dehydrated with serial ethanol cycles (70% to absolute), followed by clarification in xylol and then embedded in paraffin. Embedding was carried out with a paraffin embedding station (EG 1160; Leica). Duplicate slides of each block were obtained.

Slices of 5 μm were produced with a rotation microtome (RM 2155; Leica). Deparaffination was performed with the following protocol: Xylol 4 min; 100% EtOH 2 min; 90% EtOH 2 min; 70% EtOH 2 min; 60%. Afterwards slices were stained with Mayer hematoxylin and eosin and mounted with mounting medium (DPX). Sections were then screened under the light microscope (Leica DM LB2, Leica Microsystems) at low (x5) and high (x40) magnifications for histopathological study.

Blood sample: Blood samples (4.0 mL) were obtained from each bird for hematological studies on 0, 7 and 14 days after administration. Plasma was separated by centrifuged at 3000 g for 10 min and stored at -20°C until analysis. The levels of total protein, albumin, globuline, urea, creatinine, alkaline phosphatase (ALP), serum glutamic-oxaloacetic transaminase (SGOT or AST) and serum glutamic-pyruvic transaminase (SGPT or ALT) were measured by specific commercial kits (Roche Diagnostica, Basel, Switzerland) using an autoanalyzer (HITACHI 902 automatic autoanalyzer).

Statistical analysis: Results were expressed as Mean±Standard error of mean (SEM). Data were analyzed by one-way ANOVA using the general linear models (GLM) procedure of SAS (SAS® Institute, 2005). Multiple means comparisons were accomplished using a Duncan test. p-values less than 0.05 were considered to be significant.

Table 1: Ingredients and nutrient composition of diets

Items	Starter 1-21 days	Finisher 22-35 days
Ingredient (%)		
Corn	49.47	58.29
Soybean meal	35.00	26.40
Palm oil	6.00	6.00
Fishmeal	6.00	6.20
NaCl	0.30	0.30
Di calcium phosphate	1.40	1.20
Limestone	0.90	0.90
DL-Methionine	0.15	0.15
Lysine	0.20	-
Choline-HCl (70%)	0.08	0.06
Vitamin-mineral premix[1]	0.50	0.50
Nutrient composition		
Calculated[2]		
ME (Mcal kg^{-1})	3103.00	3205.00
Crude protein (%)	22.80	20.05
Lysine (%)	1.60	1.23
Methionine+cysteine (%)	0.90	0.70
Arginine (%)	1.55	1.31
Calcium (%)	0.97	0.92
Available phosphorus (%)	0.50	0.46

[1]Supplied per kilogram of diet: Vitamin A, 1,500 IU; Cholecalciferol, 200 IU; Vitamin E, 10 IU; Riboflavin, 3.5 mg; Pantothenic acid, 10 mg; Niacin, 30 mg; Cobalamin, 10 μg; Choline chloride, 1,000 mg; Biotin, 0.15 mg; Folic acid, 0.5 mg; Thiamine 1.5 mg; Pyridoxine 3.0 mg; Iron, 80 mg; Zinc, 40 mg; Manganese, 60 mg; Iodine, 0.18 mg; Copper, 8 mg; Selenium, 0.15 mg.
[2]Based on NRC (1994) feed composition table

RESULTS

The results of the phytochemical screening of the investigated aqueous extracts showed the presence of different types of active constituents like volatile oils, tannins, phenolic, saponins, terpenoids, steroids, flavonoid and glycosides in Table 2. However, alkaloids and steroids were only found in the aqueous extract of *Euphorbia hirta* in this study.

Bird treated with herbal extract at 2000 mg kg^{-1} b.wt. did not show any immediate behavioral changes. The birds moved and drank normally immediately after administration. After 1 h, all the birds showed signs of inappetence for 24 h after the treatment. There was no mortality till 14 day after administration (Table 3).

Macro and microscopic observations indicated no alteration in the livers and kidneys of the treated

Table 2: Phytochemical screening of selected herbal plants

	Phytochemical groups								
Samples	Volatile oils	Alkaloids	Tannins	Phenolic	Saponins	Terpenoids	Steroids	Flavonoid	Glycosides
Euphorbia hirta	+	+	+	-	+	-	+	+	+
Solanum torvum	+	-	-	+	-	-	-	+	+
Zingiber zerumbet	+	-	-	+	+	+	-	-	-
Zingiber officinale	+	-	-	+	+	+	-	-	-
Curcuma longa	+	-	+	-	+	+	-	+	-

-: Absent of phytochemical groups, +: Present of phytochemical groups

Table 3: Toxicity signs observed in broiler (first 24 h) that received oral single dose (2000 mg kg^{-1}) of the aqueous extract of herbal plants

	Sign of toxicity in acute toxicity study			
Samples	Inappetence	Unsteady gait	Tremor	Death
Euphorbia hirta	+	-	-	-
Solanum torvum	+	-	-	-
Zingiber zerumbet	+	-	-	-
Zingiber officinale	+	-	-	-
Curcuma longa	+	-	-	-

-: Absent of phytochemical groups, +: Present of phytochemical groups

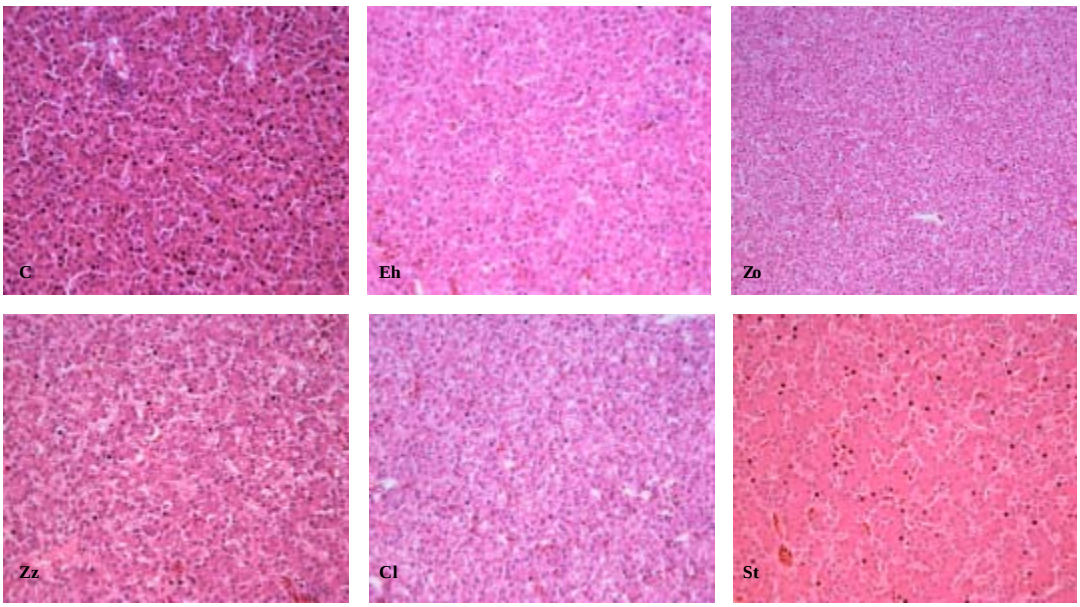

Fig. 1: Liver histology of untreated and treated broiler with aqueous extract of selected herbal plants at 2000 mg kg^{-1} b.wt., C: Control, Eh: *Euphorbia hirta*, Zo: *Zingiber officinale*, Zz: *Zingiber zerumbet*, Cl: *Curcuma longa*, St: *Solanum torvum*

birds with 2000 mg kg^{-1} of selected herbal plants extract (Fig. 1, 2).

The clinical blood chemistry examination was performed in the female broiler and the results are shown in Table 4. Serum clinical chemistry showed only a few consistent changes. The data indicate significant increases in the levels of ALT and AST treated with the aqueous extract of *Zingiber zerumbet* at the dose of 2000 mg kg^{-1} b.wt. after 7 and 14 after administration as compared to the control groups. On the other hand, a highly significant decrease in AST, ALT and ALP levels among the groups receiving the aqueous extract of *Euphorbia hirta* after 14 day of administration was observed. The highest elevation in serum ALP was observed in *Curcuma longa* group during the experimental period. Total protein, albumin, globulin, creatinine and urea levels were not different among treatment groups 7 days of administration. Following 14 days of administration, birds given *Zingiber zerumbet* had the highest blood urea level. Lowest albumin and creatinine levels were noted for those given *Curcuma longa* extract.

Table 4: Clinical blood chemistry values of female broilers administered with aqueous extract of herbal plants[1,2]

Treatments	Blood biochemical parameter							
	ALT ($U L^{-1}$)	ALP ($U L^{-1}$)	AST ($U L^{-1}$)	Total protein ($g L^{-1}$)	Albumin ($g L^{-1}$)	Globulin ($g L^{-1}$)	Creatinine ($mmol L^{-1}$)	Urea ($mmol L^{-1}$)
Before administration								
Control	2.68±0.14	2224±143	202±11.56	26.82±0.17	13.24±0.17	13.58±0.17	20.20±0.58	0.40±0.04
Solanum torvum	2.94±0.09	2318±141	184±15.09	26.76±0.85	13.52±0.12	13.24±0.30	19.40±0.97	0.36±0.04
Euphorbia hirta	2.92±0.17	2333±132	182±3.26	26.84±0.23	13.30±0.15	13.54±0.30	19.60±0.24	0.38±0.03
Zingiber officinale	2.68±0.19	2033±170	202±14.83	27.32±0.12	13.50±0.16	13.82±0.60	20.80±1.24	0.46±0.05
Curcuma longa	2.52±0.08	2162±108	190±4.09	27.26±0.10	13.42±0.27	13.84±0.20	20.20±0.66	0.40±0.04
Zingiber zerumbet	2.94±0.12	2168±170	202±14.83	27.32±0.12	13.50±0.16	13.82±0.20	20.80±1.24	0.46±0.05
7th day after administration								
Control	5.34±1.14^{b}	3339±323^{c}	263±13.11^{ab}	30.78±0.38	14.14±0.63	16.64±0.42	23.20±0.37	0.50±0.10
Solanum torvum	7.24±0.61^{b}	4302±449^{ab}	248±11.64^{ab}	29.98±1.52	12.44±0.92	17.54±0.96	24.00±1.48	0.64±0.05
Euphorbia hirta	5.98±1.19^{b}	3474±112^{bc}	231±4.22^{b}	28.86±1.55	12.34±0.60	16.52±1.07	22.40±1.02	0.62±0.06
Zingiber officinale	7.30±0.86^{b}	3679±224^{bc}	239±13.65^{b}	33.48±1.41	13.76±0.56	19.72±1.51	22.80±1.65	0.64±0.09
Curcuma longa	7.78±0.96^{b}	4538±257^{a}	238±9.99^{b}	32.74±2.81	13.60±1.41	19.14±3.26	21.00±2.89	0.62±0.11
Zingiber zerumbet	11.10±1.06^{a}	2580±172^{d}	279±13.04^{a}	31.00±1.19	13.50±0.36	17.50±1.50	22.20±1.39	0.66±0.06
14th day after administration								
Control	5.66±0.15^{b}	2531±196^{bc}	215±14.62	33.06±1.08	14.62±0.67^{a}	18.44±0.93	25.20±0.96^{ab}	0.78±0.08^{ab}
Solanum torvum	3.00±0.34^{c}	2348±134^{c}	197±14.00	32.08±1.67	14.58±0.79^{a}	17.50±1.06	24.40±0.74^{ab}	0.68±0.03^{b}
Euphorbia hirta	2.50±0.25^{c}	1526±175^{d}	193±6.43	31.40±1.92	14.34±0.81^{a}	17.06±1.24	23.80±0.86^{ab}	0.78±0.11^{ab}
Zingiber officinale	5.76±0.24^{b}	1894±113^{cd}	206±13.26	31.40±1.35	14.14±0.50^{a}	17.26±1.03	26.40±1.16^{a}	0.92±0.12^{ab}
Curcuma longa	6.58±0.37^{a}	3348±498^{a}	210±34.74	29.68±0.92	12.06±0.39^{b}	17.62±0.64	22.40±0.50^{b}	0.78±0.07^{ab}
Zingiber zerumbet	6.84±0.15^{a}	3117±155^{ab}	198±2.36	31.30±1.87	13.90±0.63^{ab}	17.40±1.52	24.40±0.97^{ab}	1.06±0.06^{a}

Means within a column with different letter(s) differ significantly ($p<0.05$), Values are expressed as Mean±SEM, n = 5, [1]: Groups were administrated orally with a single dose aqueous extract at 2000 mg kg^{-1} b.wt., [2]: Significantly different from control, $p<0.05$

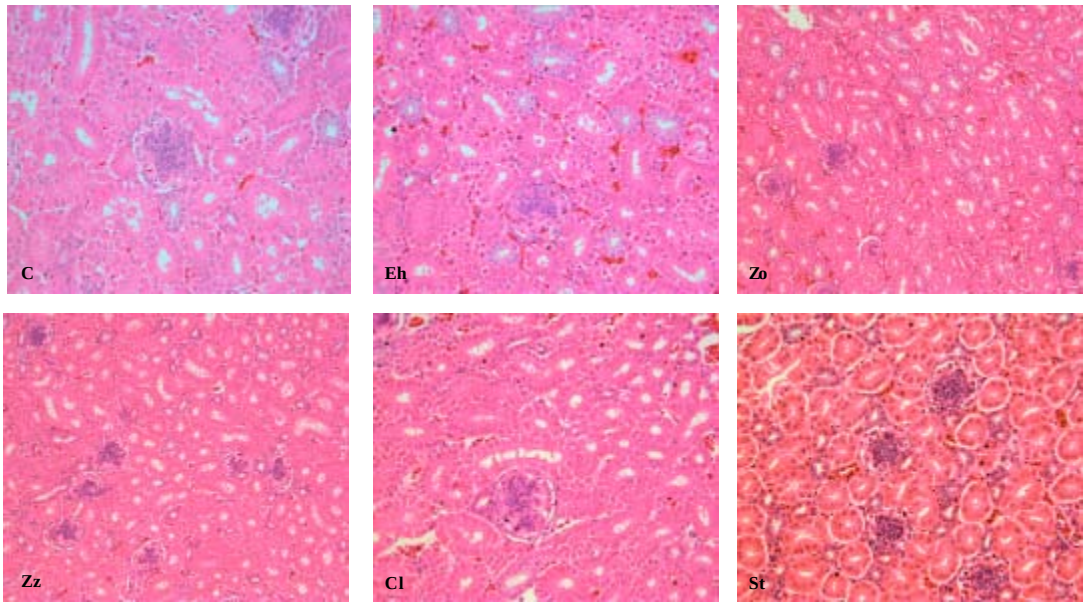

Fig. 2: Kidney histology of untreated and treated broiler with aqueous extract of selected herbal plants at 2000 mg kg^{-1} b.wt., C: Control, Eh: *Euphorbia hirta*, Zo: *Zingiber officinale*, Zz: *Zingiber zerumbet*, Cl: *Curcuma longa*, St: *Solanum torvum*

The effects of high dose aqueous extract of selected herbal plants on feed intake, body weight gain feed conversion in broilers are shown in Table 5. Following 7 days of administration body weight gains of birds that were administered with *Zingiber zerumbet* and *Zingiber officinale* were significantly greater than those of the control groups ($p<0.05$). The greatest body weight was observed in the *Zingiber zerumbet* group at 7 and 14 days after administration of high dose of aqueous extract. Birds given *Zingiber zerumbet* had higher feed consumption

Table 5: The effect of high dose aqueous extract of selected herbal plants on feed intake, body weight gain feed conversion in broilers

	Body weight gain (g)			Feed intake (g)			Feed conversion		
Treatments	21 days	28 days	35 days	21-28 days	28-35 days	21-35 days	21-28 days	28-35 days	21-35 days
Control	847±9.94	1256±18.92^{b}	1748±31.03^{ab}	964±11.55^{ab}	958±24.76^{bc}	1922±21.87^{c}	2.35±0.05^{a}	1.99±0.13^{b}	2.17±0.05^{b}
Solanum torvum	864±8.84	1348±46.64^{ab}	1875±73.03^{a}	810±19.15^{d}	993±17.09^{b}	1803±33.58^{de}	1.73±0.17^{b}	1.96±0.81^{b}	1.84±0.21^{b}
Euphorbia hirta	850±3.77	1277±13.82^{ab}	1829±29.43^{a}	924±18.74^{bc}	1125±23.06^{a}	2049±22.55^{b}	2.17±0.17^{a}	2.06±0.11^{b}	2.12±0.06^{b}
Zingiber officinale	840±7.66	1365±17.33^{a}	1677±51.73^{b}	883±19.39^{c}	970±45.66^{bc}	1853±48.10^{cd}	1.68±0.05^{b}	3.55±0.63^{a}	2.62±0.29^{a}
Curcuma longa	839±13.1	1250±13.00^{b}	1688±28.82^{b}	816±19.94^{d}	891±44.53^{c}	1707±40.35^{e}	2.00±0.10^{ab}	2.08±0.19^{b}	2.04±0.06^{b}
Zingiber zerumbet	863±9.21	1375±56.37^{a}	1891±91.63^{a}	1016±21.51^{a}	1167±27.37^{a}	2183±20.00^{a}	2.05±0.17^{ab}	2.28±0.10^{b}	2.16±0.06^{b}

Means within a column with different letter(s) differ significantly ($p<0.05$), All data are expressed as Means±SEM, Broilers were treated with aqueous extract of selected herbal plants at 2000 mg kg^{-1} b.wt.

throughout the experimental period. At 35 days of age, the poorest (2.62) feed conversion ratio values were observed in the *Zingiber officinale* group ($p<0.05$) on the other hand, comparatively better (1.84) FCR values were observed in *Solanum torvum* group.

DISCUSSION

The results of phytochemical screening provide an empirical basis for the use of these plants in traditional medicinal practices. The biological or therapeutic activities of medicinal plants are closely related to their chemicals compounds. The phytochemical screening revealed the presence of alkaloids and steroid in the aqueous extract of *Euphorbia hirta* which explains the reason of using *Euphorbia hirta* in traditional remedies for treating infectious diseases such as respiratory disease. Phytochemicals have been reported to have medicinal uses. Specially, saponin has been reported to have antimicrobial effects and could serve as precursors of steroidal substances with a wide range of physiological activities (Ojo *et al*., 2006). Alkaloids, commonly isolated from the plants, are commonly found to have antimicrobial properties (Omulokoli *et al*., 1997). Berberine is an important representative of the alkaloid group. It is potentially effective against trypanosomas and plasmodia (Freiburghaus *et al*., 1996; Omulokoli *et al*., 1997). Nicholas *et al*. (2001) screened a variety of marine extracts and identified novel alkaloid compounds with the ability to inhibit the mycobacterial (Nicholas *et al*., 2001). The mechanism of action of highly aromatic planar quaternary alkaloids such as berberine and harmane (Hopp *et al*., 1976) is attributed to their ability to intercalate with DNA (Kumar *et al*., 2007).

The toxicological evaluation of a plant extract seeks to determine its possible collateral effects, to ensure the safety of use. Some phytochemicals are able to interfere in the toxicity of herbal plants. This toxicity can be inherent of the herbal plant products or it happens during the process of extract preparation (Barros *et al*., 2005). Alldredge (1993) attributed reduced feed intake in animals fed tannin-containing diets to strong astringent property of tannins and induction of internal malaise in mammals, which may contribute to reduced feed intake in poultry. Increase in feed intake among the *Zingiber zerumbet* and *Zingiber officinale* groups could be due to zingerone`s ability to stimulate catecholamine secretion from the adrenal medulla (Diepvens *et al*., 2007). In a review of peripheral and central control of food intake, Denbow *et al*. (1989) detailed the effect of catecholamines and pancreatic polypeptides exert on feed intake regulation, especially in appetite control centers of the brain. On the other hand, in traditional medicine by *Zingiber officinale* (ginger) and *Zingiber zerumbet* are believed to have weight-loss properties, describing it as a root that stimulates digestion and speeds up the body processes. Therefore, catecholamine secretion may be explain for the increased feed intake and feed conversion ratio during experimental period.

Alterations in blood parameters may be due to changes in cellular integrity, membrane permeability of cells or even due to exposure to toxic chemicals, (Choudhari and Deshmukh, 2007). In living systems, liver is considered to be highly sensitive to toxic agents. The study of different enzyme activities such as AST (SGOT), ALT (SGPT), ALP (SALP) and total protein have been found to be of great value in the assessment of clinical and experimental liver damage. Necrosis or membrane damage releases the enzyme into circulation; therefore, it can be measured in serum. High levels of AST indicate liver damage, such as that due to viral hepatitis, cardiac infarction and muscle injury. ALT catalysis the conversion of alanine to pyruvate and glutamate and is released in a similar manner. Therefore, ALT is more specific to the liver and is thus a better parameter for detecting liver injury. The rise in the SGOT is usually accompanied by an elevation in the levels of SGPT, which plays a vital role in the conversion of amino acids to keto acids (Hoffbrand and Pettit, 1997; Dash *et al*., 2007). Serum ALP level on the other hand, is related to the function of hepatic cell. Increase in serum level of ALP is due to increased synthesis of the enzyme, in presence of increasing biliary pressure (Ojo *et al*., 2006).

It should be noted that the toxicity dose of selected plants in this study is not clear. The dose of selected herbal plants used was high, particularly, if the dose is

converted to a corresponding dose in humans (each dose of 2000 mg kg^{-1} administered in chickens in the present study would correspond to 140 g in a 70 kg person). No significant toxicity has been reported following either acute or chronic administration of *Zingiber zerumbet*, *Zingiber officinale*, *Solanum torvum* and *Curcuma longa* extracts at standard doses. These findings are consistent with those Faizah *et al.* (2002) who found that the extracts of *Zingiber zerumbet* were devoid of any mortality or behavioral changes when rats were given up to 500 mg kg^{-1} i.p in rats (Faizah *et al.*, 2002). Curcumin is the principal phenolic yellow pigment in *Curcuma longa* was given to rats, pigs and monkeys of both sexes at a dose of 300 mg kg^{-1} b.wt. No pathological, behavioural abnormalities or lethality was observed. No adverse effects were observed on both growth and the level of erythrocytes, leucocytes, blood constituents such as haemoglobin, total serum protein and ALP. Human clinical trials also indicate that curcumin has no toxicity when administered at doses of 1-8 and 10 g day^{-1} (Chattopadhyay *et al.*, 2004). In a recent report, up to 12 g of curcumin was administered in humans without significant toxicity (Poylin *et al.*, 2008). There has not been any documentation on *Solanum torvum* toxicity (Israf *et al.*, 2004).

This finding is in agreement with Ogueke *et al.* (2007) which showed that *Euphorbia hirta* ethanol extract was hematologically not toxic to rats. However, the findings of the current study do not support the earlier research by Adedapo *et al.* (2005) that showed that some chromatographic fractions of *Euphorbia hirta* have potentially deleterious effects on the serum chemistry of rats. Several aspects might explain this difference. First, it might be related to the ability of birds to tolerate high doses of plant extract as herbivorous animals to compare with rat as omnivorous animals. Second, it could be due extraction methods. There is evidence that the principal active ingredients of the plant must be more of lipid soluble or non polar, since organic solvent such hexane and ethanol, are organic solvent which must have easily extracted the lipid soluble phytochemicals (Cowan, 1999). It has been reported that plant extracts in organic solvent provided more consistent antimicrobial activity compared to those extracted in water (Parekh *et al.*, 2005). Finally, it is well known that the same taxon growing in different areas may have widely differing chemical components (Eloff, 1999). The efficacy of medicinal herbs is affected by different environmental factors. Temperature, rainfall, day length and soil characteristics are some of the factors which affect the potency of the medicinal plants. A plant may grow well in different situations, but fail to produce the same constituents (Dubey *et al.*, 2004).

Acute toxicity study indicated that water suspensions of selected herbal aqueous extract are not toxic when administered by the oral route to experimental birds at 2000 mg kg^{-1} b. wt. In conclusion, the results obtained in the present study are in agreement to a certain degree with the traditional uses of the plants estimated. Additionally, based on the results of the liver enzymes study, apart from the traditional uses, *Euphorbia hirta* may also act as a prophylactic agent to prevent liver diseases. The present results could be a good basis for selection of plant species for further investigation in the potential discovery of new natural bioactive compounds. In addition, these plants could represent striking feed additive agents, which provide prophylaxis against various diseases, growth and health promoter.

ACKNOWLEDGMENTS

This study was supported by a grant (05-01-04-SF0182) from the Ministry of Science, Technology and Innovation, Malaysia. The authors gratefully acknowledge S. Zulkepli, M. Ebrahimi and M. Tabatabaei for their technical assistance.

REFERENCES

Adedapo, A.A., M.O. Abatan, S.O. Idowu and O.O. Olorunsogo, 2005. Effects of chromatographic fractions of *Euphorbia hirta* on the rat serum biochemistry. Afr. J. Biomedical Res., 8: 185-189.

Alçiçek, A., M. Bozkurt and M. Çabuk, 2004. The effects of a mixture of herbal essential oil, an organic acid or a probiotic on broiler performance. South Afr. J. Anim. Sci., 34: 217-222.

Alldredge, J., 1993. The Effect of Condensed Tannins on Browsers and Grazers: Quantitative and Qualitative defense. 1st Edn., Colorado State University, Fort Collins, Colorado.

Araujo, C.A.C. and L.L. Leon, 2001. Biological activities of *Curcuma longa* L. Mem. Inst. Oswaido Cruz, 96: 723-728.

Arthan, D., J. Svasti, P. kittakoop, D. Pittayakhachonwut and M. Tanticharoen *et al.*, 2002. Antiviral isoflavonoid sulfate and steroidal glycosides from the fruits of *Solanum torvum*. Phytochemistry, 59: 459-463.

Barros, S., C.D. Ropke, T.C. Sawada, H.V.V. Silva and S.M.M. Pereira *et al.*, 2005. Assessment of acute and subchronic oral toxicity of ethanolic extract of *Pothomorphe umbellata* L. Miq (Pariparoba). Braz. J. Pharm. Sci., 41: 53-61.

Bhandari, U., J.N. Sharma and R. Zafar, 1998. The protective action of ethanolic ginger (*Zingiber officinale*) extract in cholesterol fed rabbits. J. Ethnopharmacol., 61: 167-171.

Chattopadhyay, I., K. Biswas, U. Bandyopadhyay and R.K. Banerjee, 2004. Turmeric and curcumin: Biological actions and medicinal applications. Curr. Sci., 87: 44-53.

Choudhari, C.V. and P.B. Deshmukh, 2007. Acute and subchronic toxicity study of *Semecarpus anacardium* on haemoglobin percent and RBC count of male albino rat. Herbal Medicine Toxicol., 1: 43-45.

Cowan, M.M., 1999. Plant products as antimicrobial agents. Clin. Microbiol. Rev., 12: 564-582.

Dahiru, D., J.A. Onubiyi and H.A. Umaru, 2006. Phytochemical screening and antiulcerogenic effect of *Moringa oleifera* aqueous leaf extract. Afr. J. Traditional Complementary Alternative Med., 3: 70-75.

Dash, D.K., V.C. Yeligar, S.S. Nayak, T. Ghosh and D. Rajalingam *et al*., 2007. Evaluation of hepatoprotective and antioxidant activity of *Ichnocarpus frutescens* (Linn.) on paracetamol-induced hepatotoxicity in rats. Trop. J. Pharm. Res., 6: 755-765.

Denbow, D.M., G.E. Duke and S.B. Chaplin, 1989. Food intake, gastric secretion and motility as affected by avian pancreatic polypeptide administered intraceberebrally in chickens. Peptides, 9: 449-454.

Diepvens, K., K.R. Westerterp and M.S. Westerterp-Plantenga, 2007. Obesity and thermogenesis related to the consumption of caffeine, ephedrine, capsaicin and green tea. Am. J. Physiol. Regulatory Integrative Comparative Physiol., 292: 77-85.

Dubey, N.K., R. Kumar and P. Tripathi, 2004. Global promotion of herbal medicine: India's opportunity. Curr. Sci., 86: 375-41.

Eloff, J.N., 1999. It is possible to use herbarium specimens to screen for antibacterial components in some plants. J. Ethnopharmacol., 67: 355-360.

Evans, W.C., 2002. Trease and Evans Pharmacognosy. 5th Edn., W.B. Saunders Ltd., London, ISBN: 0-7020-2617-4, pp: 119-159.

Faizah, S., M.N. Somchit and M.H. Shukriyah, 2002. *Zingiber zerumbet* (Lempoyang): A potential anti-inflammatory agent. Proceedings of the Regional Symposium on Environment and Natural Resources, April 10-11, Kuala Lumpur, Malaysia, pp: 516-520.

Freiburghaus, F., R. Kaminsky, M.H.H. Nkunya and R. Brun, 1996. Evaluation of African medicinal plants for their *in vitro* trypanocidal activity. Ethnopharmacology, 55: 1-11.

Haughton, P.J. and A. Raman, 1998. Laboratory Handbook for the Fractionation of Natural Extracts. 1st Edn., Clapman and Hall, USA., ISBN: 0-412-74910-6.

Hernandez, F., J. Madrid, V. Gargia, J. Orengo and M.D. Megias, 2004. Influence of two plant extracts on broiler performance, digestibility and digestive organ size. Poult. Sci., 83: 169-174.

Hoffbrand, A.V. and J. E. Pettit, 1997. Essential of Haematology. 4th Edn., Blackwell Science Inc., USA., ISBN: 0-632-05153-1.

Hopp, K.H., L.V. Cunningham, M.C. Bromel, L.J. Schermeister and S.K.W. Khalil, 1976. *In vitro* antitrypanosomal activity of certain alkaloids against *Trypanosoma lewisi*. Lloydia, 39: 375-377.

Hore, S.K., V. Ahuja, G. Mehta, P. Kumar and S.K. Pandey *et al*., 2006. Effect of aqueous *Euphorbia hirta* leaf extract on gastrointestinal motility. Fitoterpia, 77: 35-38.

Israf, D.A., N.H. Lajis, M.N. Somchit and M.R. Sulaiman, 2004. Enhancement of ovalbumin-specific IgA responses via oral boosting with antigen co-administered with an aqueous *Solanum torvum* extract. Life Sci., 75: 397-406.

Khattak, S., S.U. Rahman, H.U. Shah, W. Ahmad and M. Ahmad, 2005. Biological effect of indigenous medicinal plants *Curcuma longa* and *Alpina galangal*. J. Fitoterpia, 76: 254-257.

Kumar, G.S., K.N. Jayaveera, C.K.A. Kumar, U.P. Sanjay and B.M.V. Swamy *et al*., 2007. Antimicrobial effects of Indian medicinal plants against acne-inducing bacteria. Tropical J. Pharmaceutical Res., 6: 717-723.

National Research Council, 1994. Nutrient Requirements of Poultry. 9th Revised Edn. National Academy Press, Washington, DC., USA, ISBN-10:0-309-04892-3.

Nicholas, G.M., G.L. Newton, R.C. Fahey and C.A. Bewley, 2001. Novel bromotyrosine alkaloids: Inhibitors of mycothiol S-conjugate amidase. Organic Lett., 3: 1543-1545.

Ogueke, C.C., J.N. Ogbulie, I.C. Okoli and B.N. Anyanwu, 2007. Antibacterial activities and toxicological potentials of crude ethanolic extracts of *Euphorbia hirta*. J. Am. Sci., 3: 11-16.

Ojo, O.O., M.S. Nadro and I.O. Tella, 2006. Protection of rats by extracts of some common Nigerian trees against acetaminophen-induced hepatotoxicity. Afr. J. Biotechnol., 9: 755-760.

Omulokoli, E., B. Khan and S.C. Chhabra, 1997. Antiplasmodial activity of four Kenyan medicinal plants. Ethnopharmacology, 56: 133-137.

Parekh, J., D. Jadeja and S. Chanda, 2005. Efficacy of aqueous and methanol extracts of some medicinal plants for potential antibacterial activity. Turk. J. Biol., 29: 203-210.

Poylin, V., M.U. Fareed, P. O'Neal, N. Alamdari and N. Reilly *et al*., 2008. The NF-êB inhibitor curcumin blocks sepsis-induced muscle proteolysis. Mediators Inflammation, 2008: 1-13.

Sakinah, S.A.S., S.T. Handayani and A.L.P. Hawariah, 2007. Zerumbone induced apoptosis in liver cancer cells via modulation of Bax/Bcl-2 ratio. Cancer Cell Int., 4: 1-11.

Sofowora, A., 1993. Screening Plants for Bioactive Agents: Medicinal Plants and Traditional Medicine in Africa. 2nd Edn., Spectrum Books Ltd., Ibadan.

Somchit, M.N., M.H.N. Sukriyah, A.A. Bustammam and A. Zuraini, 2005. Anti-pyretic and analgesic activity of *Zingiber zerumbet*. Int. J. Pharmacol., 277: 277-280.

Wray, C. and R.H. Davies, 2000. Competitive exclusion-An alternative to antibiotics. Vet. J., 59: 107-108.

Zhang, K.Y., F. Yan, C.A. Keen and P.W. Waldroup, 2005. Evaluation of microencapsulated essential oils and organic acids in diets for broiler chickens. Int. J. Poult. Sci., 4: 612-619.